

Cirurgia no Tromboembolismo Pulmonar Crônico

Tratamento Cirúrgico da HP no TEP Crônico

Renato A. K. Kalil

Cirurgião Cardiovascular do Instituto de Cardiologia RGS/FUC e Hospital Moinhos de Vento
Professor-Associado de Cirurgia da UFCSPA
Professor Emérito do Programa de Pós-Graduação do IC/FUC
Pesquisador CNPq

kalil@cardiologia.org.br



Nome do Palestrante: Renato A. K. Kalil

Título da Apresentação:

Cirurgia no Tromboembolismo Pulmonar Crônico

**Não possuo nenhum conflito de interesse
relacionado a esta apresentação**

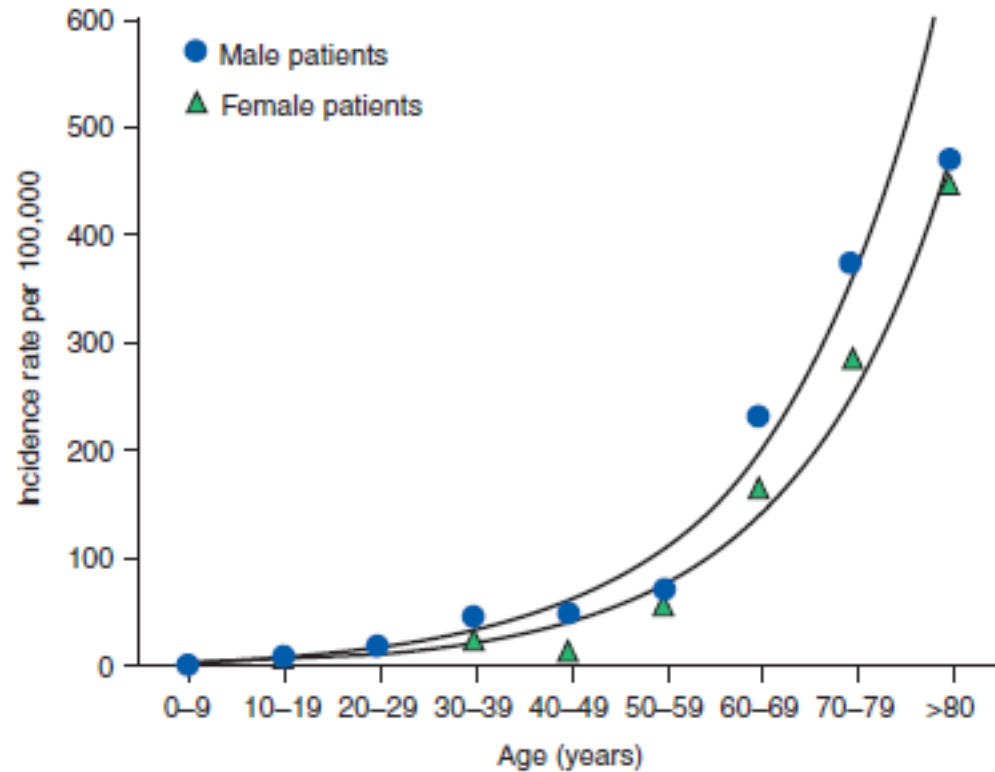


FIGURE 55-2 Annual incidence of venous thromboembolism in the United States stratified for age. Males have a significantly higher incidence rate of venous thromboembolism than females. Both curves fit an exponential function. (Reproduced, with permission, from Anderson FA Jr, Wheeler HB, Goldberg RJ, et al: A population-based perspective of the hospital incidence and case fatality rates of deep vein thrombosis and pulmonary embolism: the Worcester DVT study. *Arch Int Med* 1991; 151:933.)

Algumas Estimativas

500 TVP:100.000 hab/ano

RGS = 12.000.000 hab = 60.000 TVP por ano

90% das embolias pulmonares associadas a TVP

2/3 das TVP são assintomáticas

Em 1987 estimativa de 500.000 sobreviventes de embolia pulmonar por ano nos EUA

0,5% evolui para HP por TEP crônico = 2.500 por ano

Hoje = 5 - 10X maior: até 25.000 casos por ano

Estima-se que 100.000 pessoas nos EUA tenham HP tratável por endarterectomia

Corresponderia no RGS a 4.000 casos

Table I. Revised World Health Organization (WHO) Classification of Pulmonary Hypertension.

WHO Group	Description
Group I	Pulmonary arterial hypertension (PAH) and other subtypes of PAH
Group II	Left heart disease
Group III	Respiratory disease and hypoxemia
Group IV	Chronic thromboembolic pulmonary hypertension (CTEPH)
Group V	Miscellaneous causes

Adapted from McLaughlin et al.¹

Hipertensão Pulmonar por TEP Crônico

- ***Sub-diagnosticada***
- ***Sub-tratada***
- ***Sem sintomas
específicos***
- ***Pneumologia***
- ***Cardiologia***
- ***Angiologia***
- ***Cirurgia torácica***
- ***Cirurgia
cardiovascular***

Hipertensão Pulmonar por TEP Crônica

- Doença:



Tema negligenciado na literatura de cirurgia cardiovascular

Cirurgia para TEP Crônico

Histórico

1º Relato: Allison, 1960: hipotermia de superfície, transesternal, remoção trombos recentes

Relatos esparsos 1965 – 1995

Braunwald em San Diego, 1970

Jamieson, 1993: 150 casos em 29 meses

*Jamieson SW: Pulmonary thromboendarterectomy, in Franco KL, Putnam JB (eds): *Advanced Therapy in Thoracic Surgery*. Hamilton, Ontario, BC Decker, 1998; pp 310-318.*

Adoção lenta em poucos centros/ Resultados heterogêneos

Tratamento Cirúrgico de Tromboembolismo Pulmonar Crônico

Gabriel Lorier Taranto, Paulo Moreno, Renato A. K. Kalil

Porto Alegre, RS

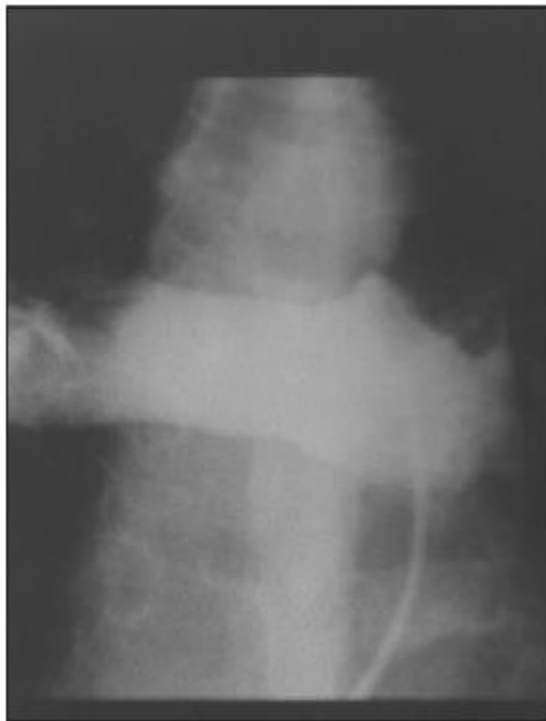

Fig. 1 - Arteriografia pulmonar mostrando a interrupção ao fluxo de contraste na artéria pulmonar esquerda após sua origem.

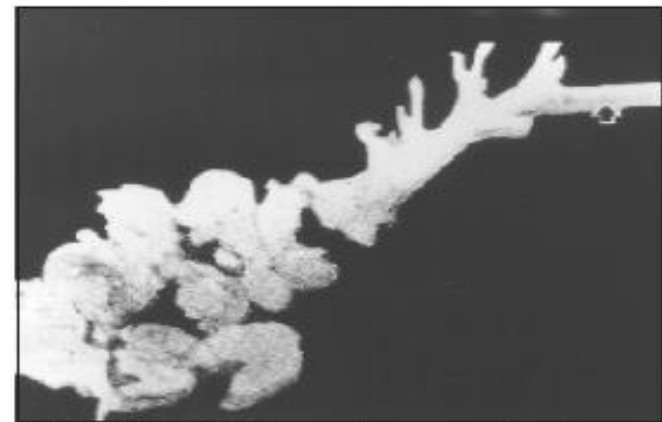


Fig. 2 - Tromboembolos crônicos organizados, extraídos da paciente após a tromboendarterectomia pulmonar em paciente operado por toracotomia médio-esternal extraíndo-se material do nível proximal da artéria pulmonar

Pac. feminina, 22 anos, obesa, hipertensa, dispnéia progressiva

*Guest
Editorial*

Surgical Pulmonary Embolectomy

The Resurrection of an Almost Discarded Operation

Samuel Z. Goldhaber, MD

Imagine a scenario in which an operation is declared a failure before the skin incision is made, regardless of the results.

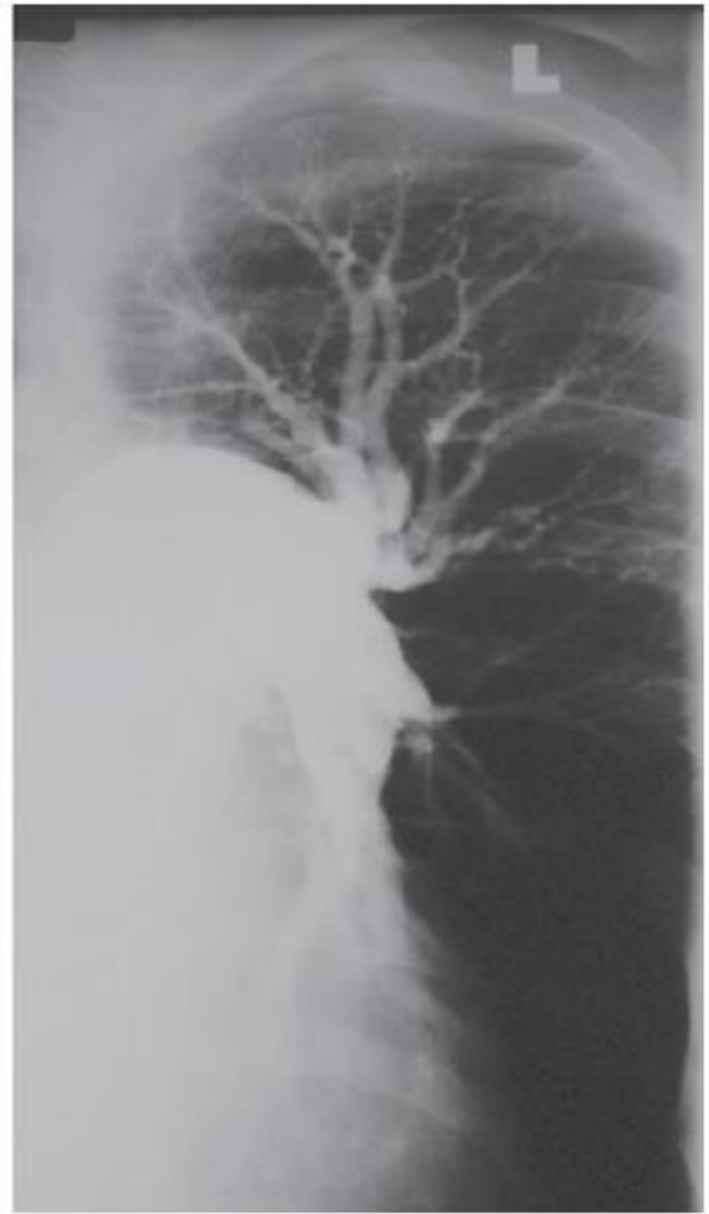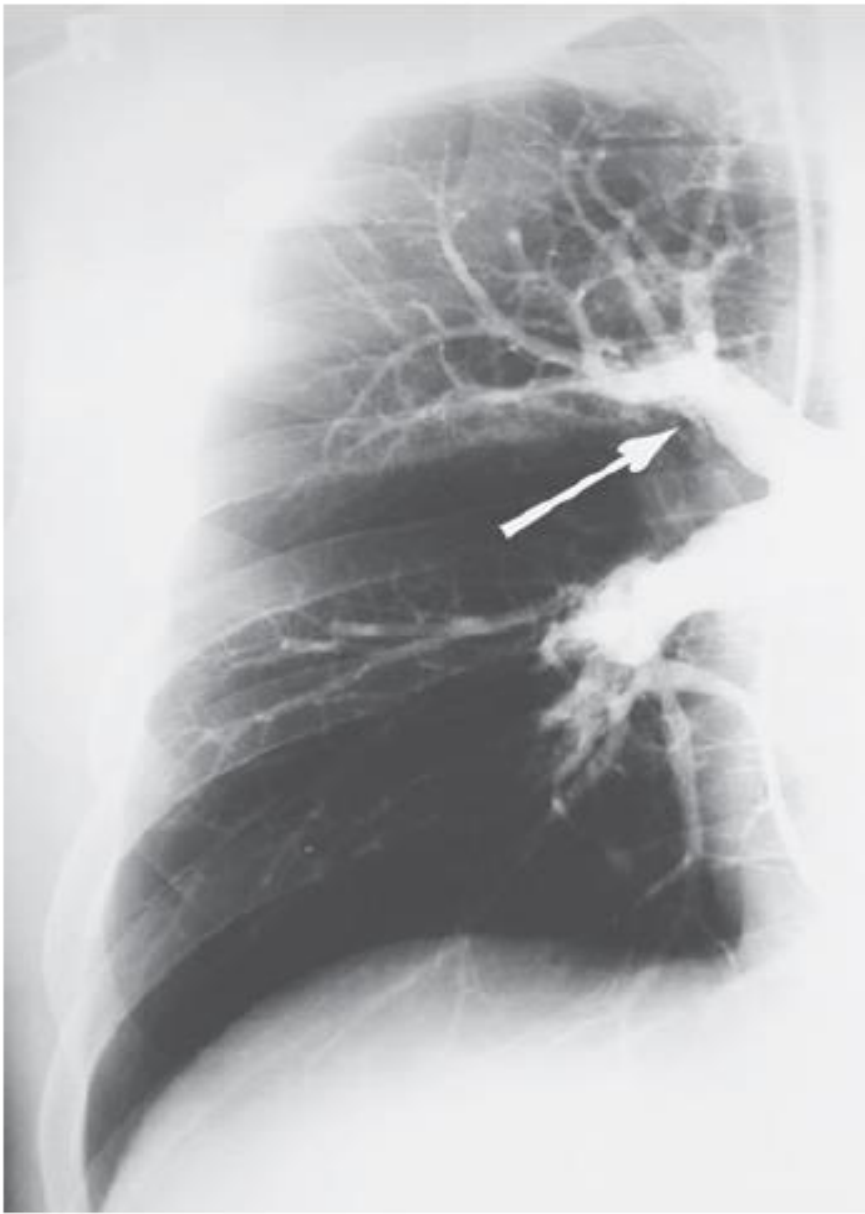
In the case of pulmonary embolectomy, this is exactly what happened. If patients survived the surgery, critics declared that the operation was unnecessary. And the harshest critics were cardiac surgeons. They berated their usually junior colleagues for operating on these patients, because patients who survived were supposedly not sufficiently ill to warrant surgery. On the other hand, if patients died postoperatively, the operation itself was declared futile, and the surgeon who operated was chastised for wasting resources, for being impulsive, and for not knowing when to say “no.” When such cases were reviewed at morbidity and mortality conferences, senior cardiac surgeons would often impose an informal moratorium on pulmonary embolectomy.

Texas Heart Inst Journal 2013

Argumentos semelhantes válidos para TEP crônico

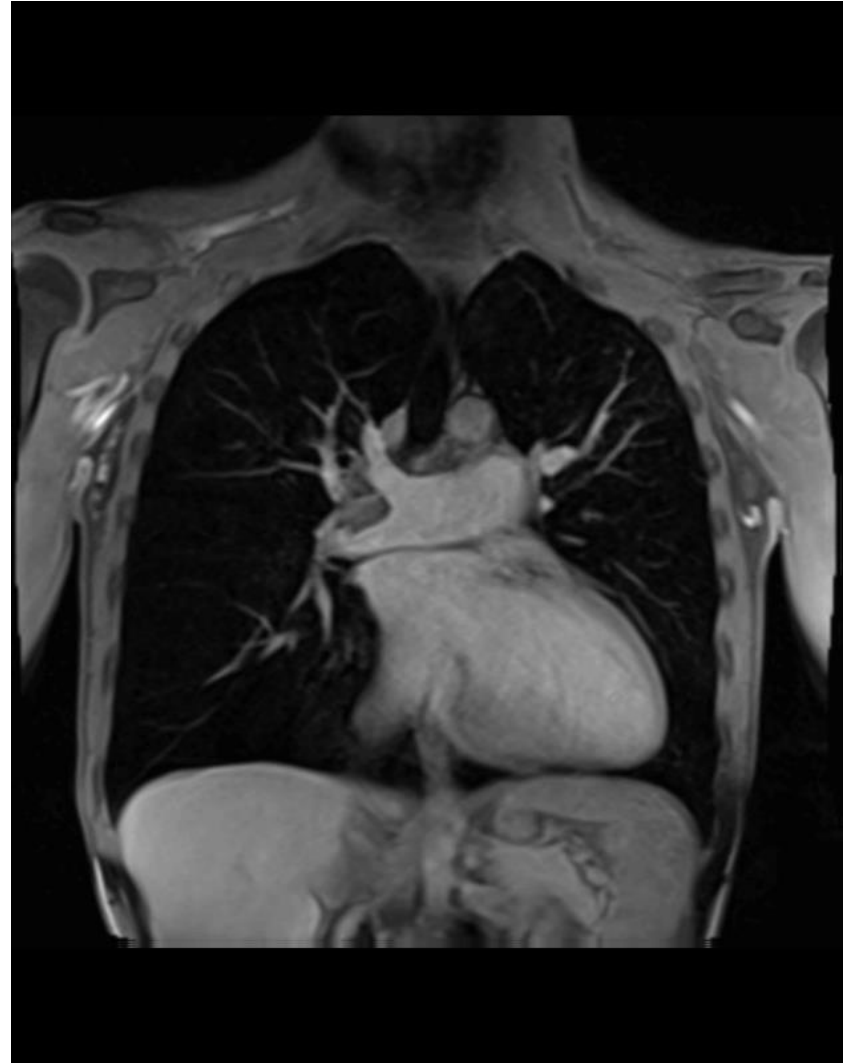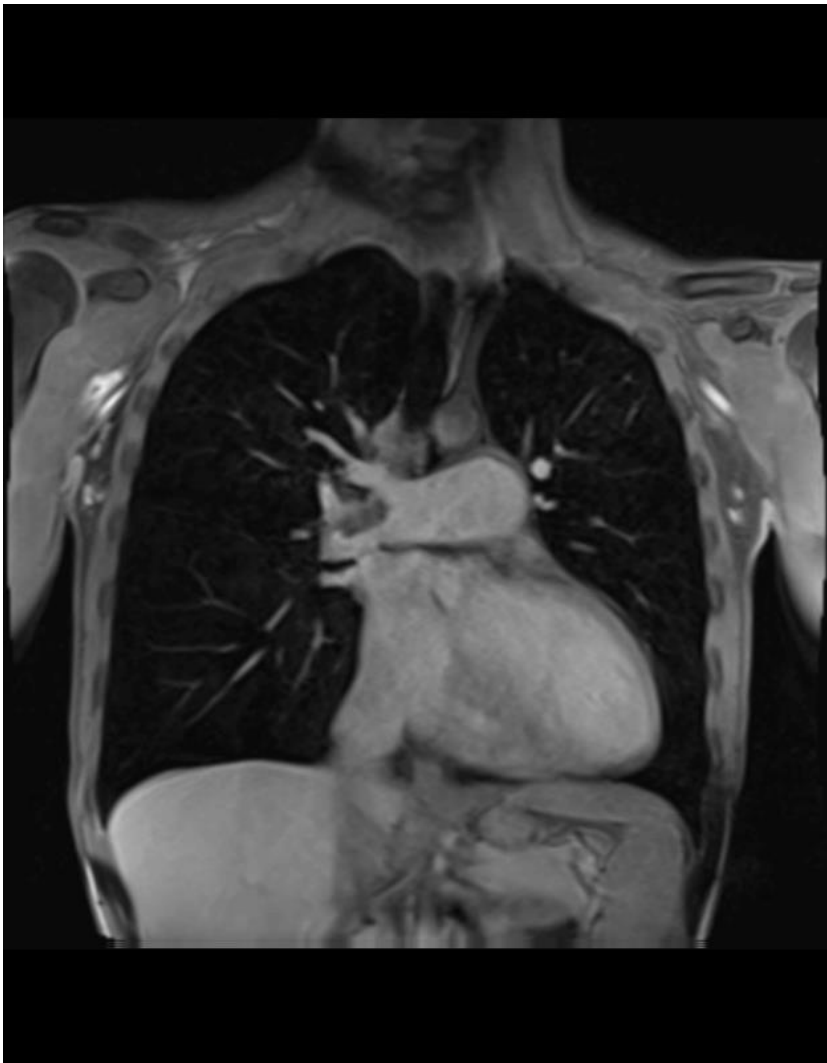Indicação Cirúrgica

- Diagnóstico TEP comprovado por exames de imagem (Rx, Angiografia, AngioTC, AngioRMN, Cintilografia)
- Gravidade dos sintomas
- Hipertensão pulmonar (sem limite superior)
- *Conceito atual: tratamento da HP por TEP crônico = cirurgia ou cirurgia ou cirurgia*



Right and left pulmonary angiograms demonstrate enlarged pulmonary arteries, poststenotic dilatation
Madani & Jamieson, in Cohn: Cardiac Surgery in the Adult, 4th Ed. 2012

Angioressonância de tórax



Ex: 14153

11

SIDI Medicina por Imagem

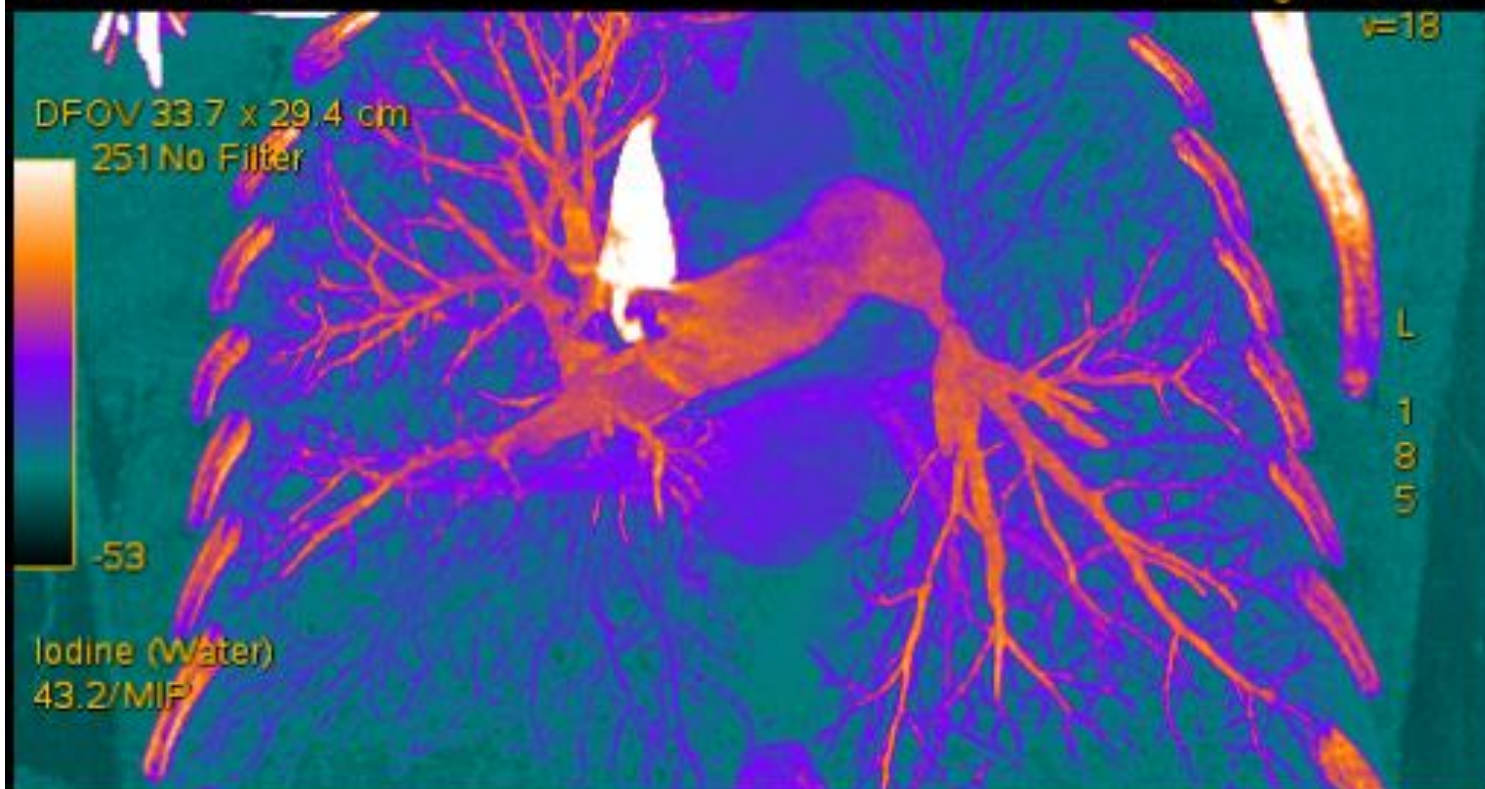
F 51 1387106

Se:3 GSI

DoB: Mar 01 1963

Vaso 1 P: 11.73

Ex: Aug 07 2014



1.2mm 0.984:1/0.62sp

Tilt: 0.0 GSI-1 Material Density

08:55:13 AM m=-53.0 M=251.0

W=304.0 L=99.0 100ug/cm3

I 295

Razões para Tromboendarterectomia

Moser 3 razões:

1. Hemodinâmica, para tratar VD
2. Alvéolo-respiratória, para perfundir parênquima ventilado
3. Profilática, para prevenir falência VD e progressão retrógrada da trombose

4ª razão (Madani/Jamieson): prevenção de arteriopatias secundárias pela HP nos demais vasos

Princípios da Cirurgia de TEP

- *Bilateral*
- *Esternotomia mediana*
- *Arteriotomias abertas*
- *Circulação extracorpórea e hipotermia*
- *Endarterectomia completa, nível da média*
- *Trombos recentes são incomuns ou limitados*

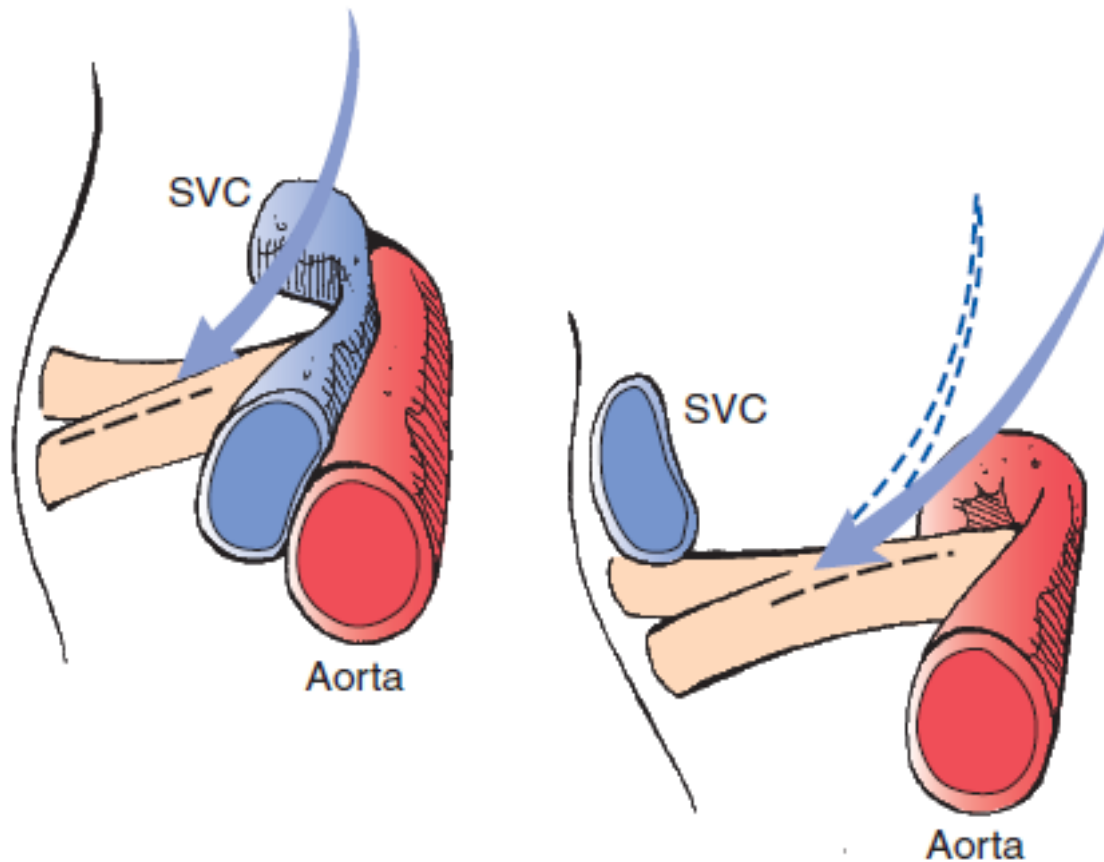


FIGURE 55-7 Recommended surgical approach on the right side. This approach, medial to the superior vena cava (SVC), between the superior vena cava and aorta, provides a direct view into the right pulmonary artery. Note that an approach on the lateral side of the superior vena cava will only provide a restricted view, and should be avoided.

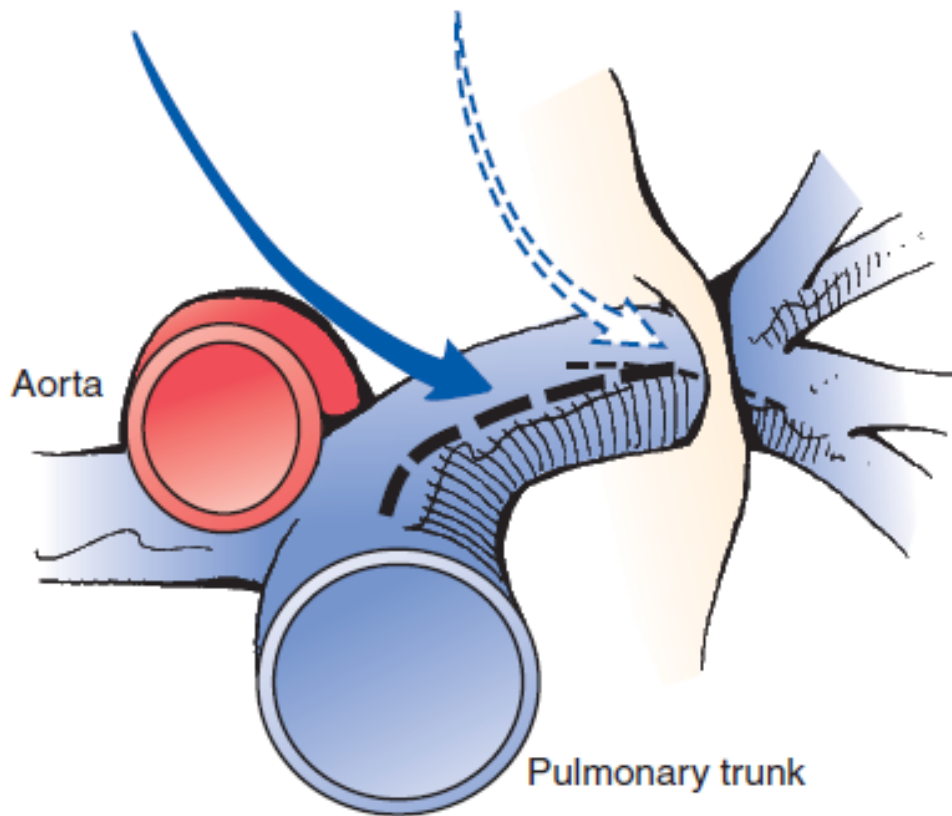


FIGURE 55-12 Surgical approach on the left side. The incision in the left pulmonary artery begins in the midpoint of the main pulmonary trunk, at the insertion site of the pulmonary artery vent. This incision provides better visibility than a more distal approach (*dotted line and arrow*). Care must be taken to avoid injury to the phrenic nerve.

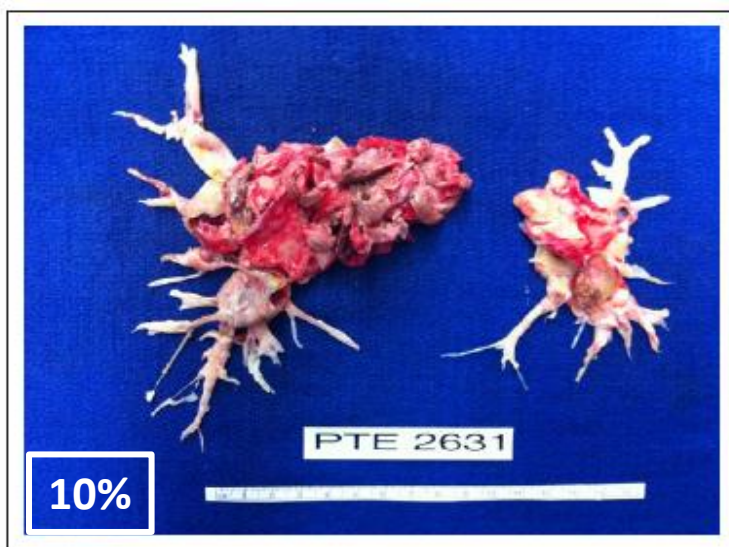

Figure 3. Type I disease with clot in the main pulmonary arteries.

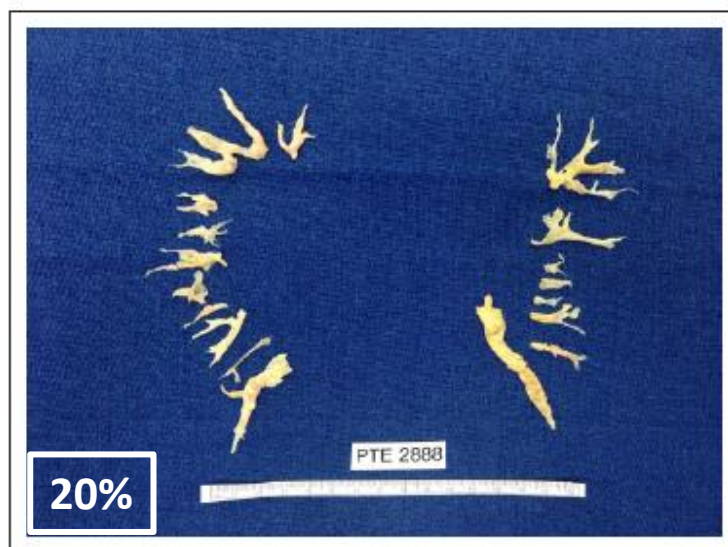


Figure 5. Type III disease with dissection plane raised in the segmental branches to remove clot as far out as the subsegmental level.

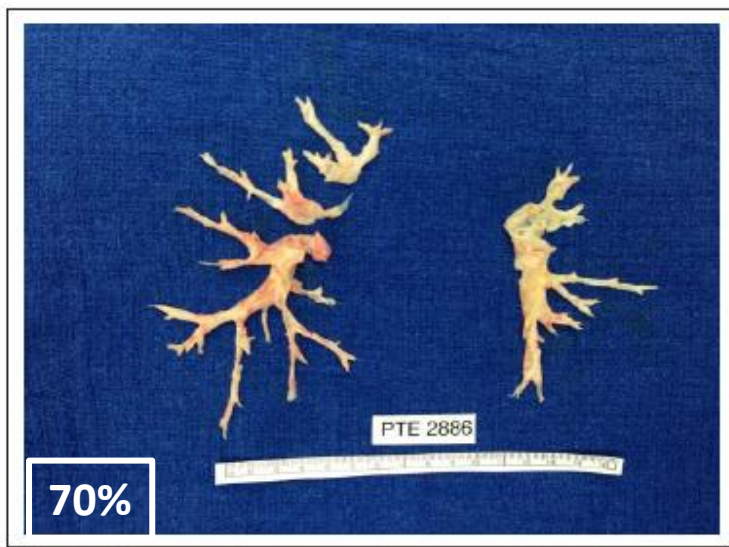


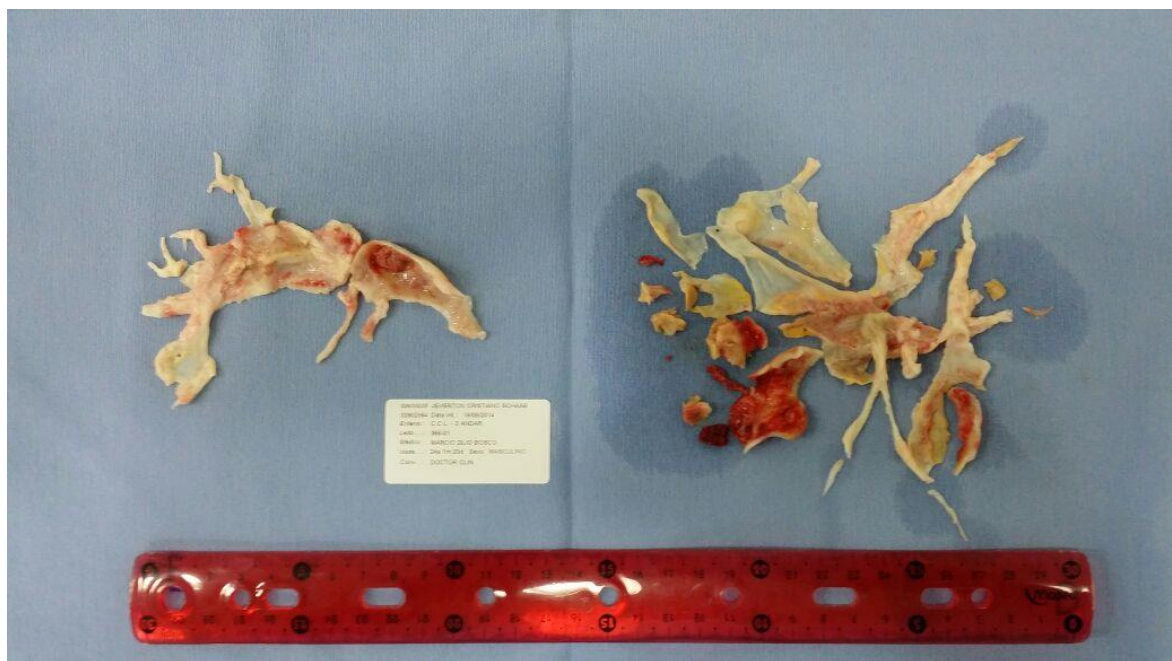
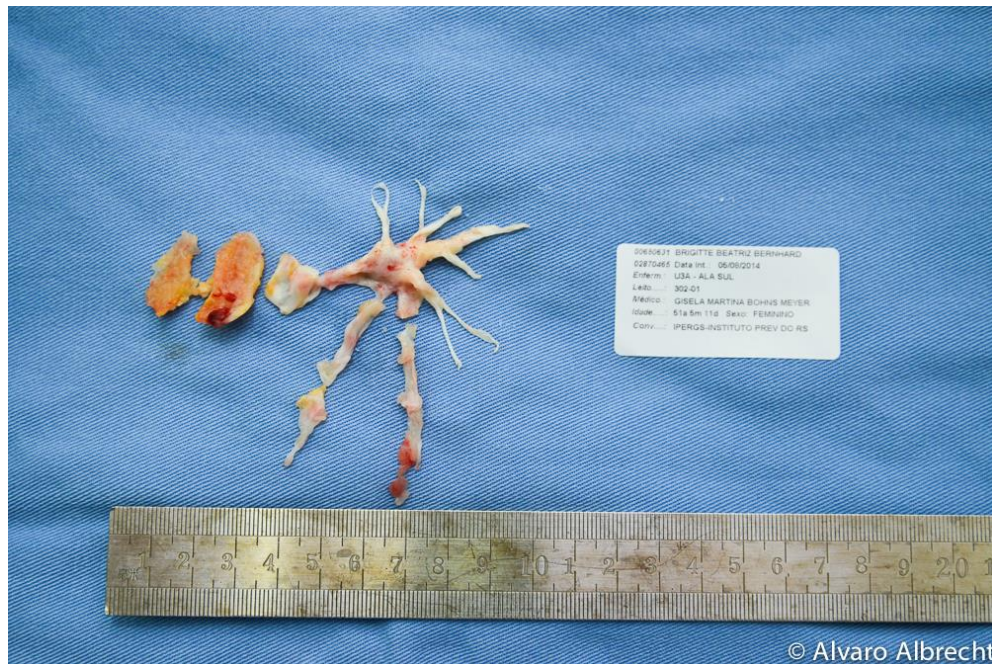
Figure 4. Type II disease with clot in the lobar arteries where the dissection plane was raised.

arteriotomy is repaired. To perform the left endarterectomy, the surgeon moves to the patient's right side. Once endarterectomies are completed on both sides, CPB is reinstated and warming is commenced. Methylprednisolone (500 mg) and mannitol (12.5 g) are administered; this is in addition to methylprednisolone present in the pump prime (see the following discussion). If a patent foramen ovale (PFO) is present, it is repaired, and other indicated cardiac procedures, such as coronary artery bypass and mitral or aortic valve surgery, are performed during the rewarming period. Wound closure is routine, with hemostasis being important because the patient will receive anticoagulation treatment within hours of reaching the intensive care unit (ICU).³

Anesthetic Management

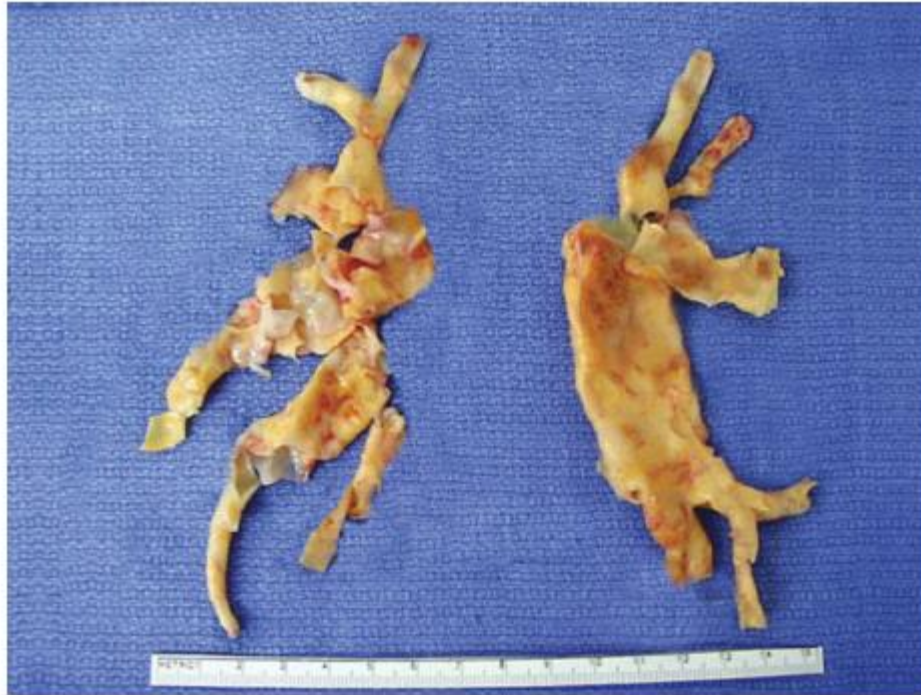

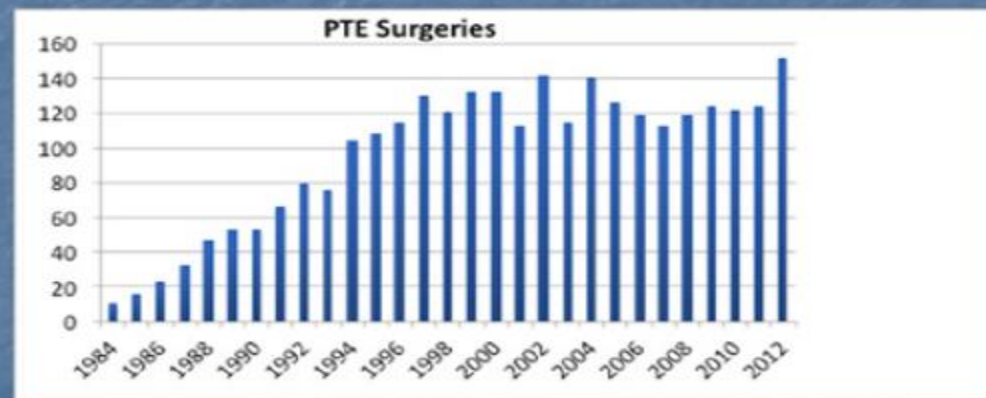FIGURE 55-11 Note the absence of distal “tails” in this specimen removed from a patient with surgical classification type IV. All “tails” are replaced by “trousers”. No clinical benefit was obtained from this procedure and the patient’s postoperative hemodynamics were not improved, despite what appears to be an impressive endarterectomy specimen. The patient had primary pulmonary hypertension.



A UCSD Surgical Experience 1984 - 2012



B Perioperative Mortality Rates: UCSD

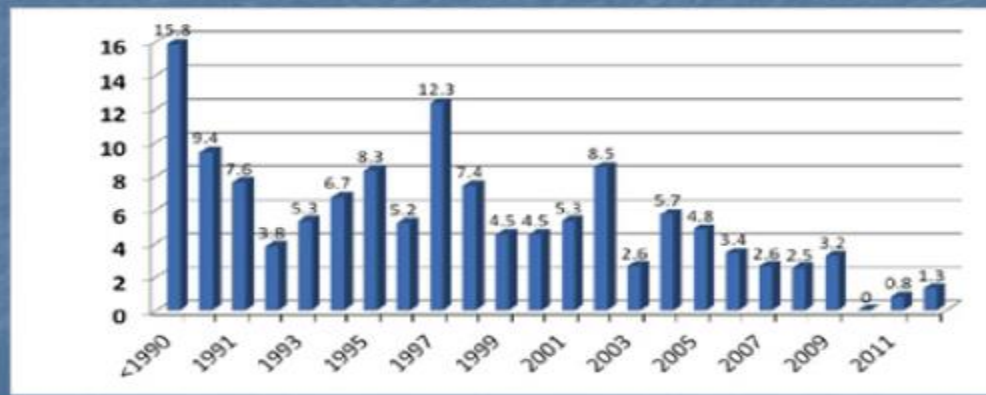


Figure 15. (A) University of California, San Diego surgical experience from 1984 to 2012. (B) University of California, San Diego perioperative mortality rates from 1990 to 2012.

Pós-operatório

- Ventilação mecânica (overnight)
- Volume corrente alto
- Extubação no 1º p.o.
- Diurese provocada, balanço hídrico negativo
- Ht > 30%
- Filtro de veia cava inferior?
- Anticoagulação – RNI 2,5 a 3

Complicações

- Além das relacionadas a cirurgia cardíaca:
- Hipertensão pulmonar persistente: *NO/fármacos*
- Edema de reperfusão: *ECMO/perfusão veno-venosa*
- Complicações neurológicas: *delírio, perda cognitiva*

Resultado Hemodinâmico

- *Redução Pressão Arterial Pulmonar*
- *Redução Resistência Arterial Pulmonar*
- *Aumento Fluxo Pulmonar*
- *Aumento do Rendimento Cardíaco*
- *Melhora da Classe Funcional*
- *Remodelamento VD*
- *Reversão de Insuficiência Tricúspide*

Evolução Tardia

aos 6 anos p.o.:

- Sobrevida = 75%
- Classe funcional NYHA I ou II = 95%
- Retorno ao trabalho = 62%
- Melhora Qualidade Vida, mas ainda inferior ao normal
Resposta a questionário: 75% muito melhor
20% melhor

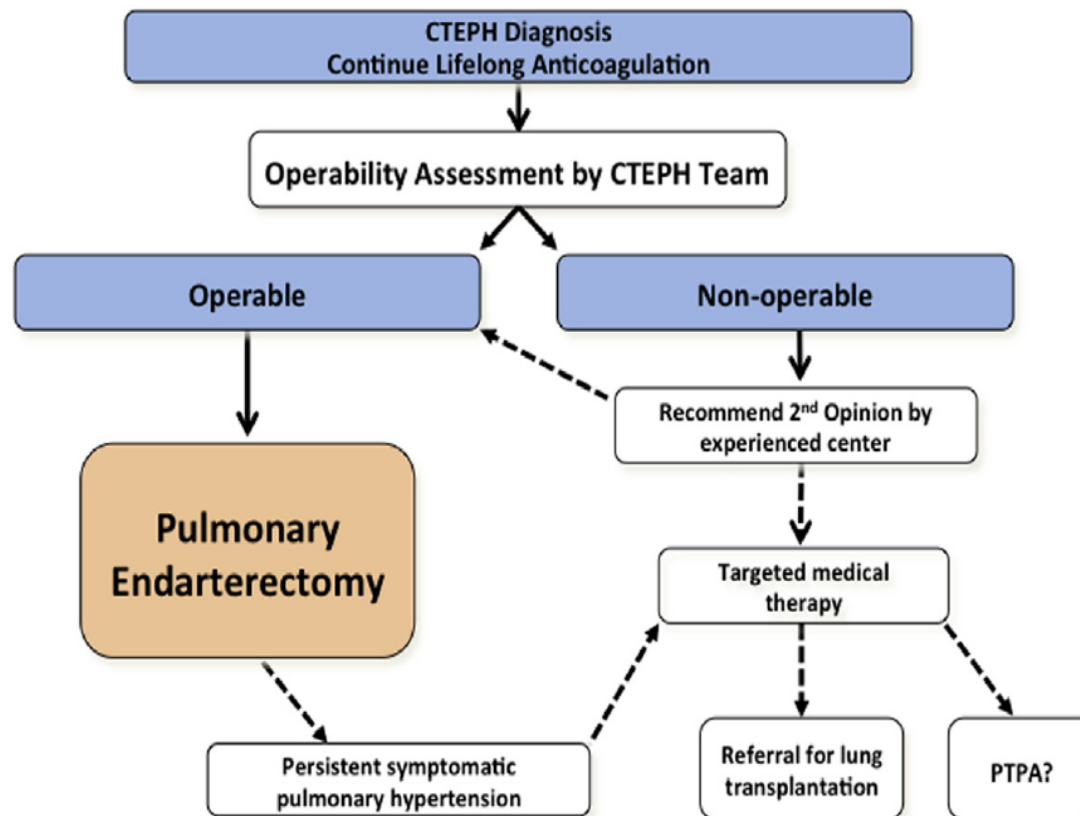


Figure 2 CTEPH: Treatment Algorithm

Once the diagnosis of CTEPH is made, all patients should receive life-long anticoagulation therapy unless contraindicated. All patients with CTEPH should be referred for operability assessment by an experienced CTEPH team to determine if the patient is operable and candidate for pulmonary endarterectomy. If a patient is deemed non-operable, we recommend consideration for a second opinion by an experienced CTEPH team. This recommendation is in recognition of operability definition being subjective and dependent on center experience, and mirroring the operability adjudication process utilized in recent randomized controlled trials of medical therapy. For patients deemed non-operable, or patients after pulmonary endarterectomy with persistent symptomatic PH, treatment with PH targeted medical therapy is recommended. Other treatment options in select cases may include lung transplantation or percutaneous transluminal pulmonary angioplasty. PTPA = percutaneous transluminal pulmonary angioplasty; other abbreviations as in [Figure 1](#)

The Future

PEA is now recognized as the definitive treatment of CTEPH.

With increased awareness of the disease and referral of patients early in the disease process, PEA will become an increasingly common operation.

However, because morbidity and mortality rates are still significant, continued research into etiology, diagnosis, medical management, and surgical treatment are necessary.

Residual pulmonary hypertension, RPE, vascular steal, RV failure, and cerebral protection remain areas of research that will likely result in improved outcomes.

Cirurgia no Tromboembolismo Pulmonar Crônico

Tratamento Cirúrgico da HP no TEP Crônico

Renato A. K. Kalil

Cirurgião Cardiovascular do Instituto de Cardiologia RGS/FUC e Hospital Moinhos de Vento
Professor-Associado de Cirurgia da UFCSPA
Professor Emérito do Programa de Pós-Graduação do IC/FUC
Pesquisador CNPq

kalil@cardiologia.org.br

